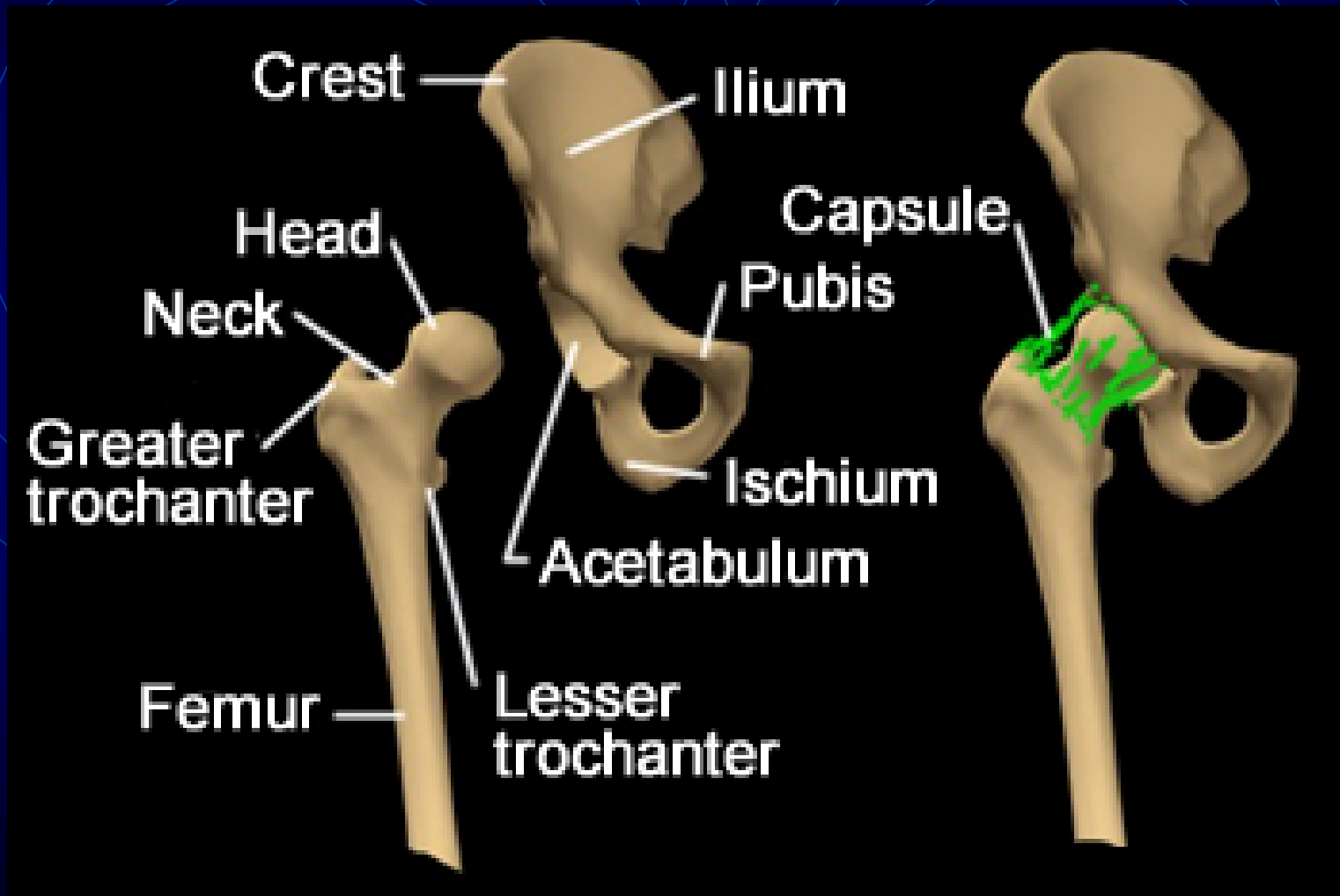


The background is a dark blue gradient. It features several sets of concentric circles in a lighter blue color, centered at different points. These circles overlap each other. Additionally, there are several thin, light blue lines that intersect at various points, creating a geometric pattern. Some of these lines are dashed, while others are solid.

# *Hip Arthroplasty*

# *Anatomy of Hip*



# *Hip Joint*

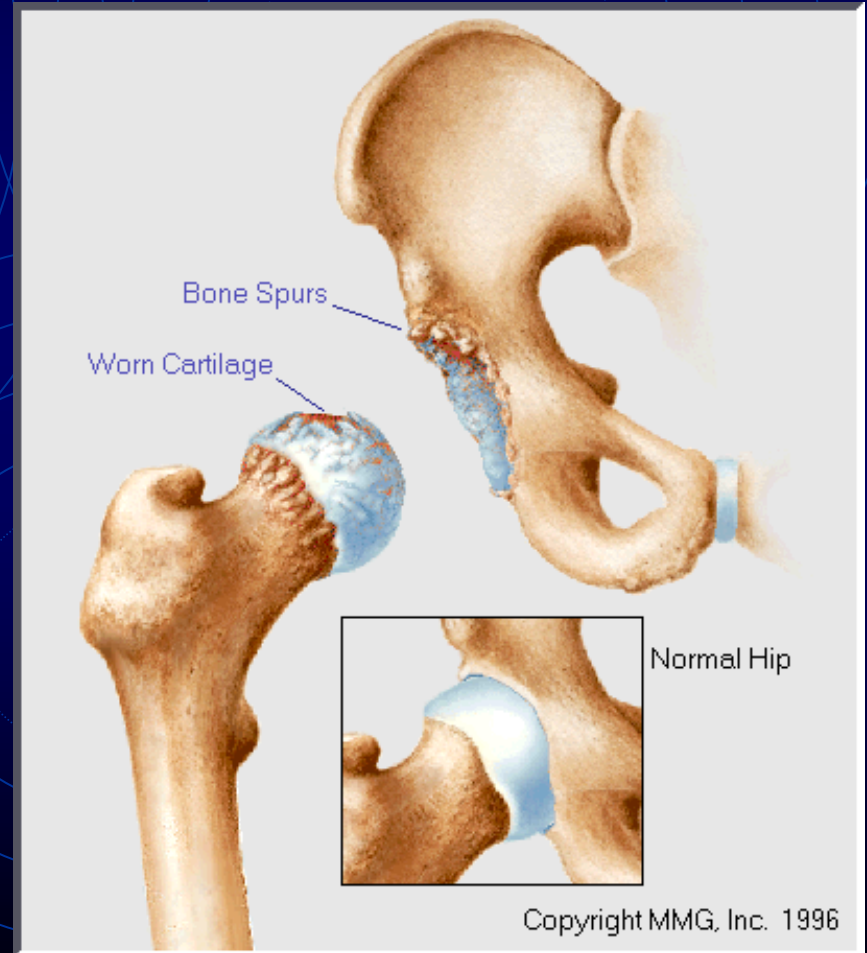
- **Ball and socket**
  - Ball is the femoral head
  - Socket is Acetabulum
    - Half sphere depression
    - Lined with cartilage
      - Horseshoe shape

# *Hip Joint*

- Femur
  - Neck-shaft angle  $\sim 135^{\circ}$
  - $2/3^{\text{rd}}$  of head is covered with cartilage
  - Head fits into acetabulum
    - Suction effect during dislocation

# *Hip OA*

- Cartilage gradually wear down
  - Femoral head and acetabulum grind on each other (bone-on-bone arthrosis)



# *Traumatic arthritis*

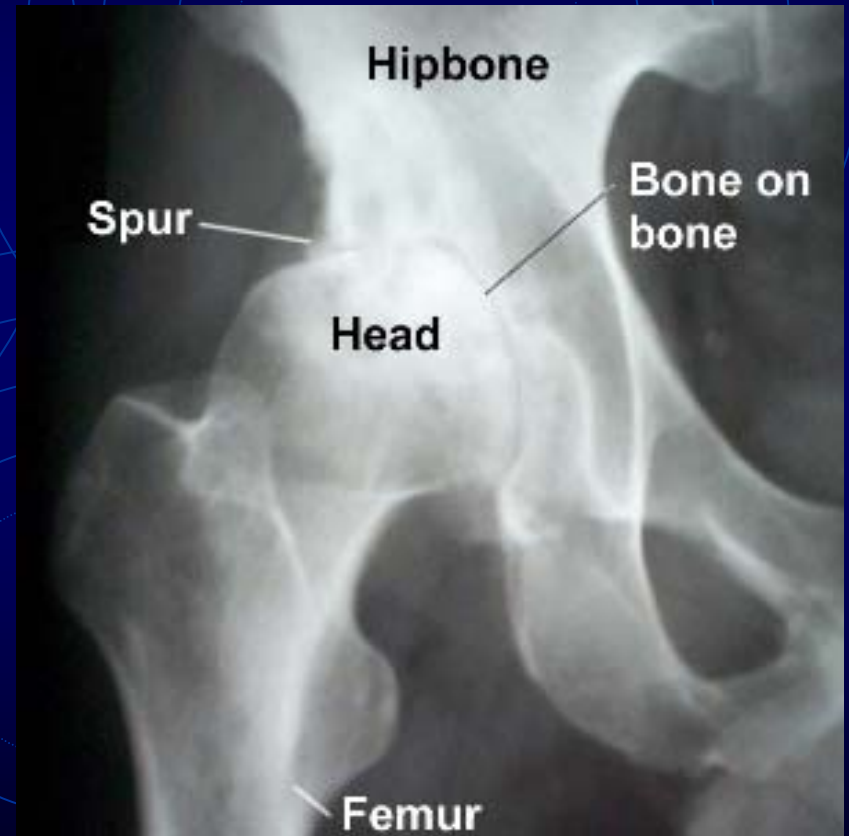- Occurs following injury to hip
  - Direct trauma
    - damage to cartilage
  - Femoral neck fracture
  - Hip dislocation
    - Blood supply may be lost
      - Avascular necrosis

# *Rheumatoid arthritis*

- Body's immune system attacks synovium and cartilage
  - Joint arthrosis
  - Deformity
  - Stiffness
  - Women are more often affected than men

# *Plain X-rays*

- Loss of joint space
- Subchondral sclerosis
- Subchondral Cysts
- Irregularity of joint surface
- Subluxation



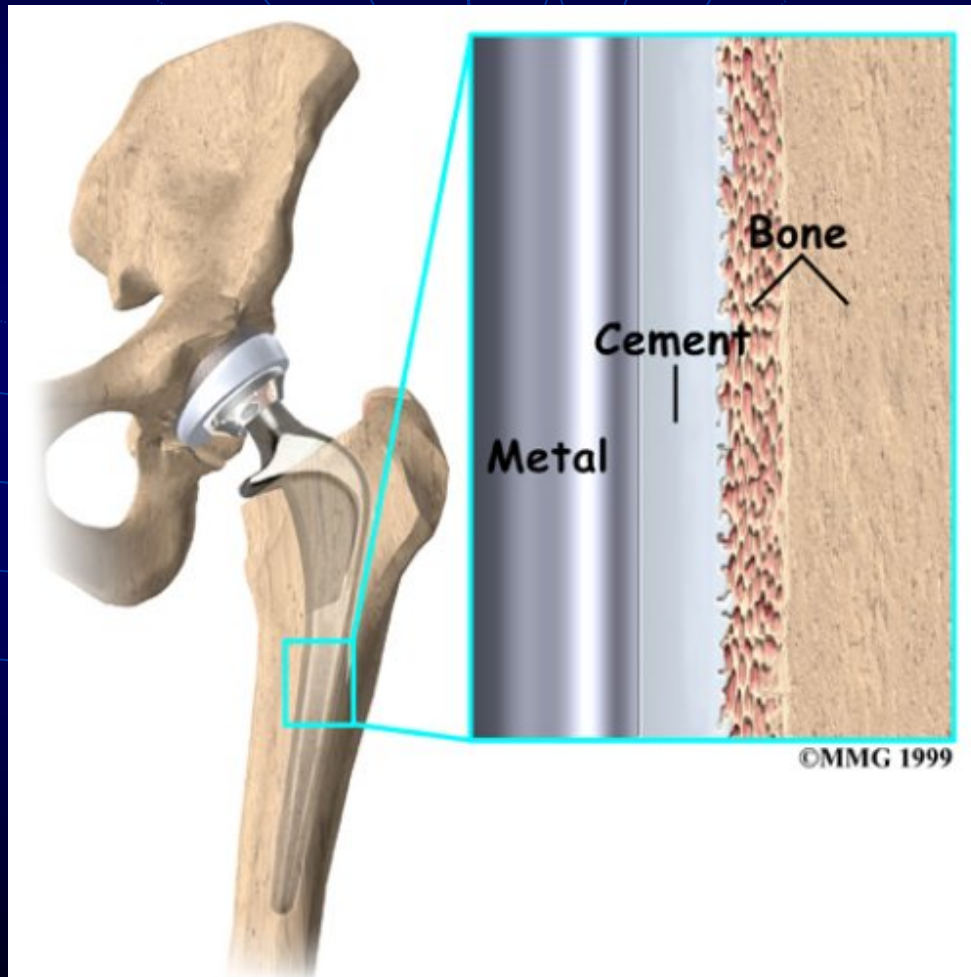
# *Objectives*

- Joint replacement
- Femoral stem
  - IM Metal implant
    - Modular
      - Titanium stem and cobalt-chrome head
- Acetabular cup
  - A low-wearing plastic insert
    - Press fit to acetabulum
    - Porous coated

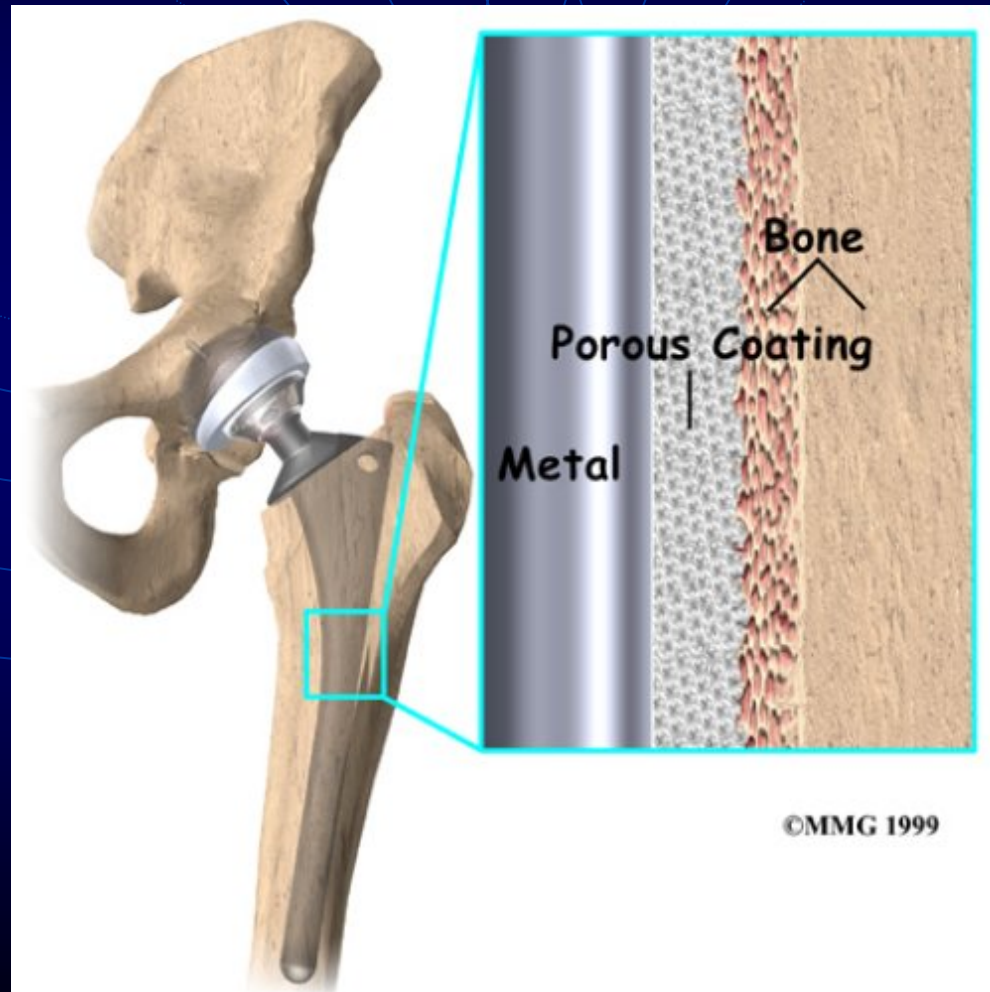
# *Types of Implants*

- Implants may be
  - Cemented
  - Porous coated
    - Mesh of holes on implant surface
    - Secured as bone in grows

# *Cemented type*

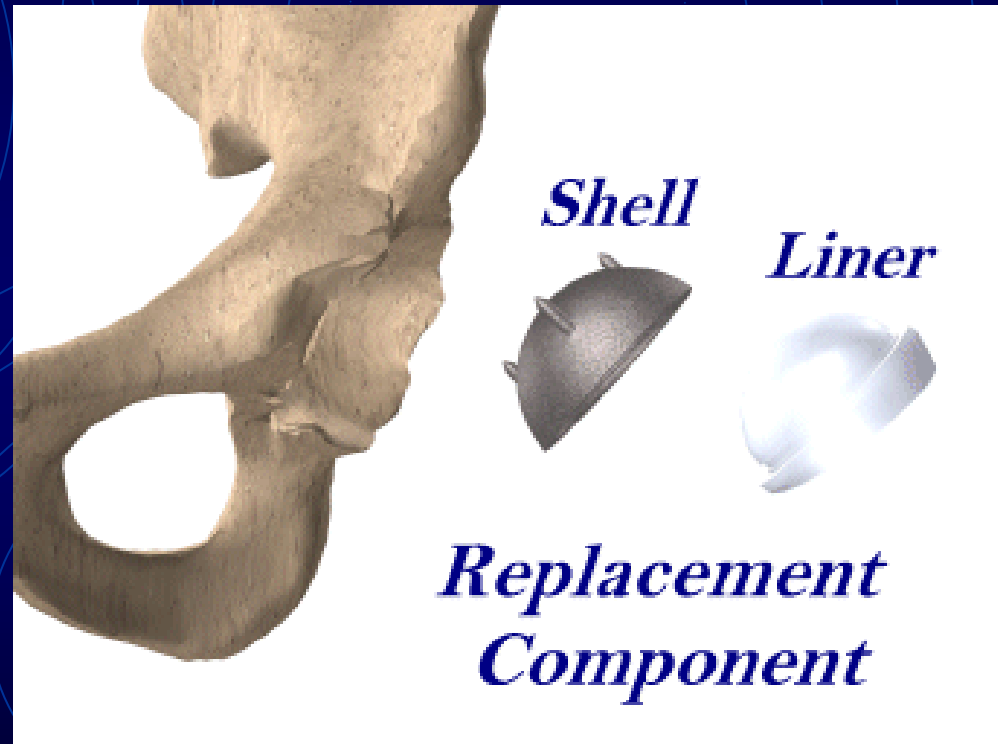


# *Porous Coated Implants*



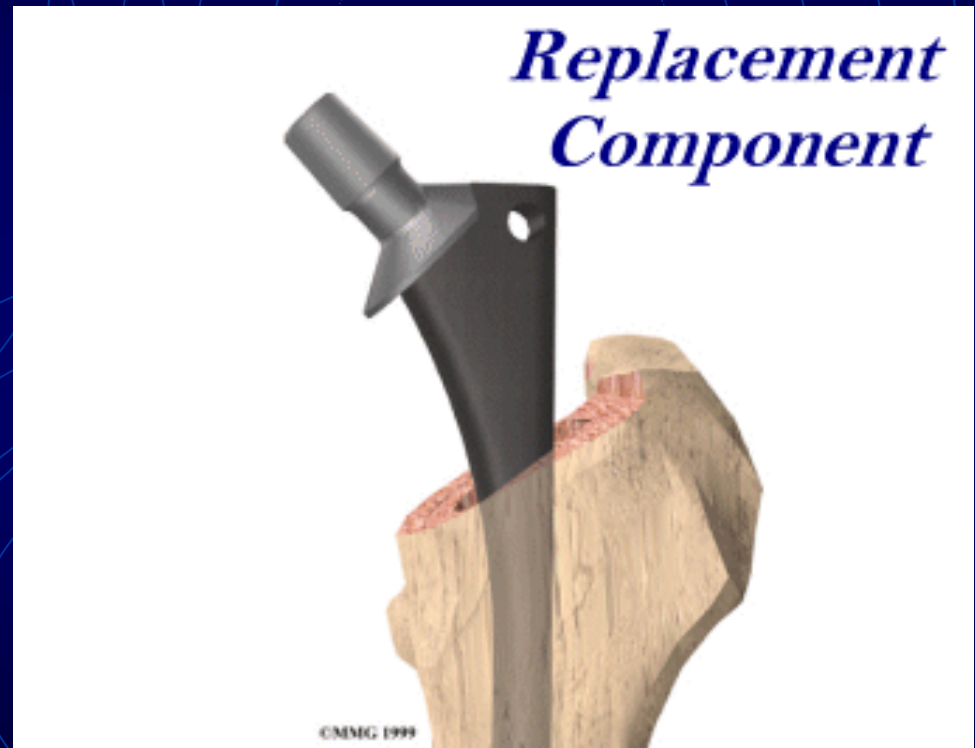# *Acetabular component*

- Shell is made of metal
- Plastic liner
  - Load bearing
  - Fits snugly inside shell



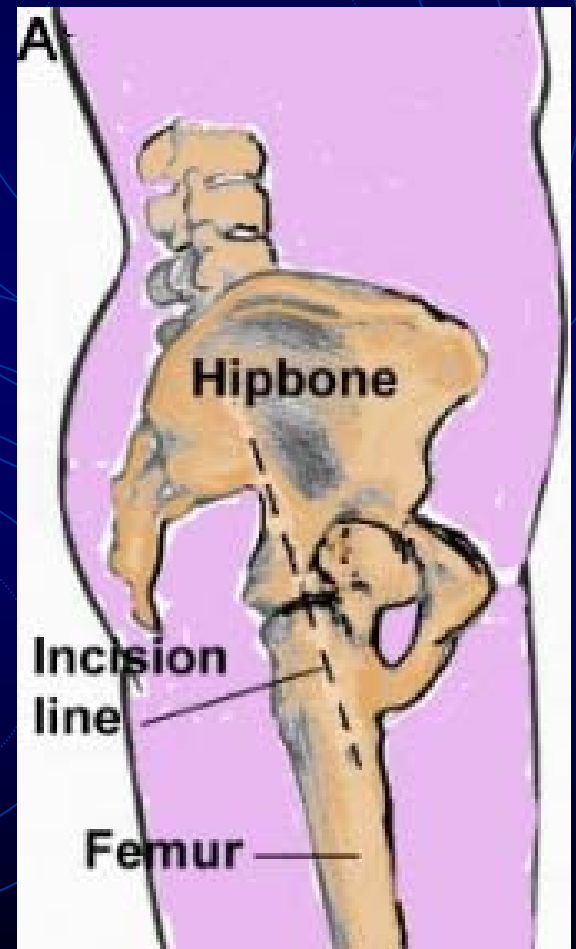
# *Femoral Stem*

- Made of metal
  - Usually titanium
  - Head
    - Diameter
      - 28, 32 mm
    - Material
      - Cobalt chrome
      - Ceramic



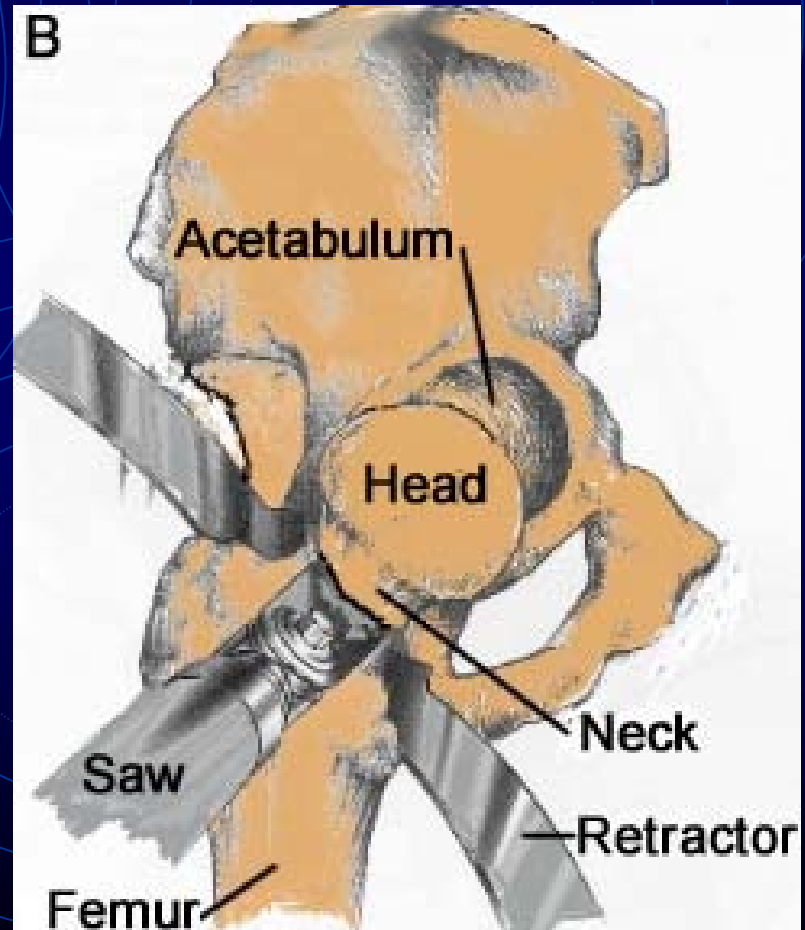
# *Surgical Procedure*

- An incision about eight inches long (dotted line)
- Exposure hip joint
  - Anterior
  - Posterior

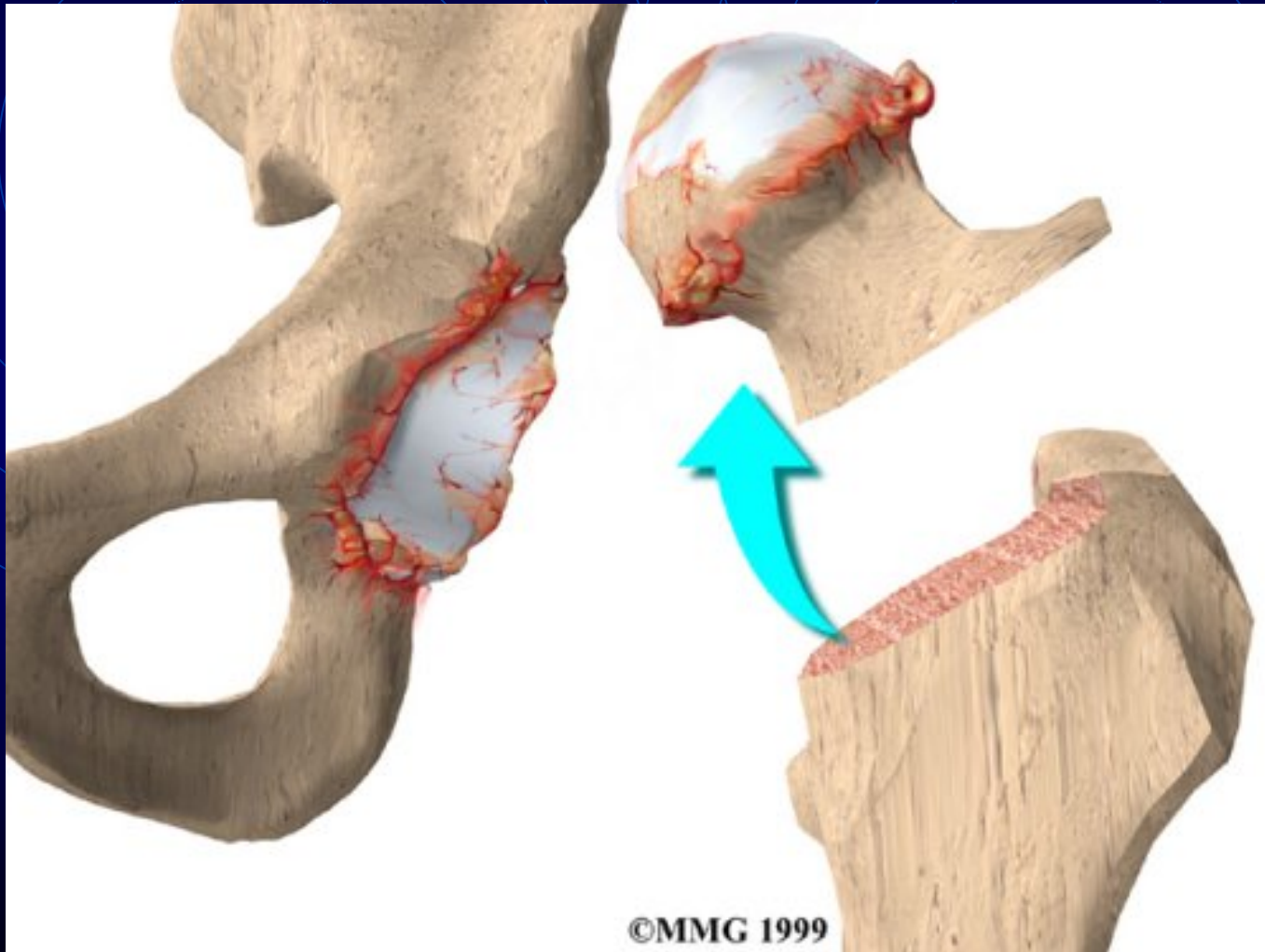


# *Removal of Femoral Head*

- Femoral head is dislocated from acetabulum
- Neck cut
  - Femoral head is removed

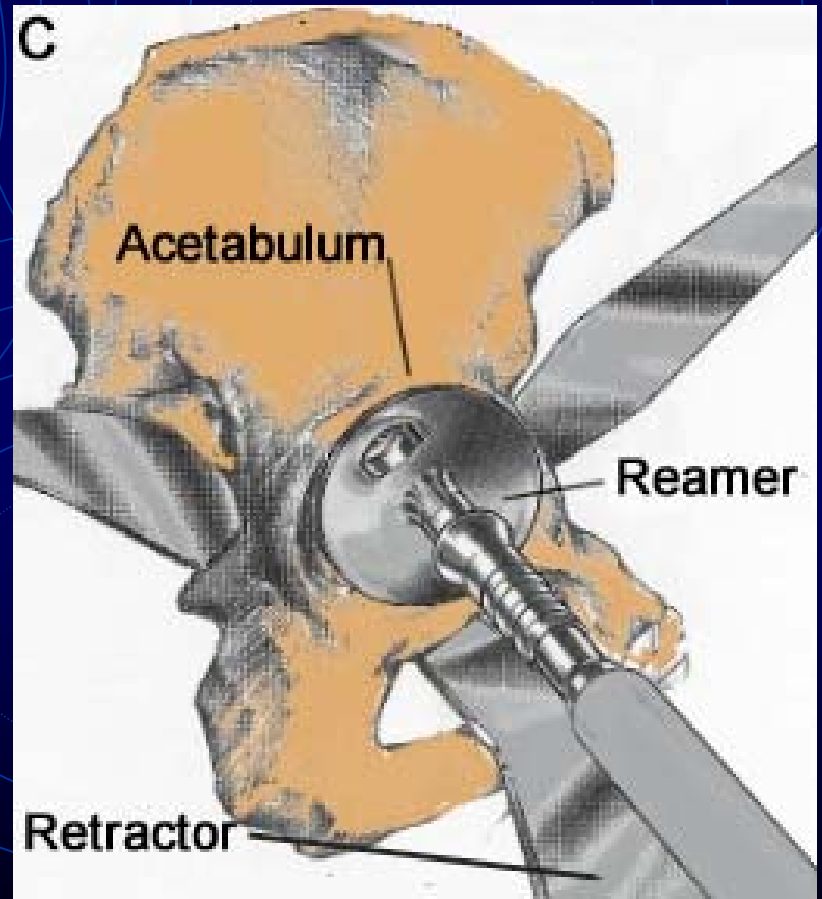


# *Femoral Neck Cut*



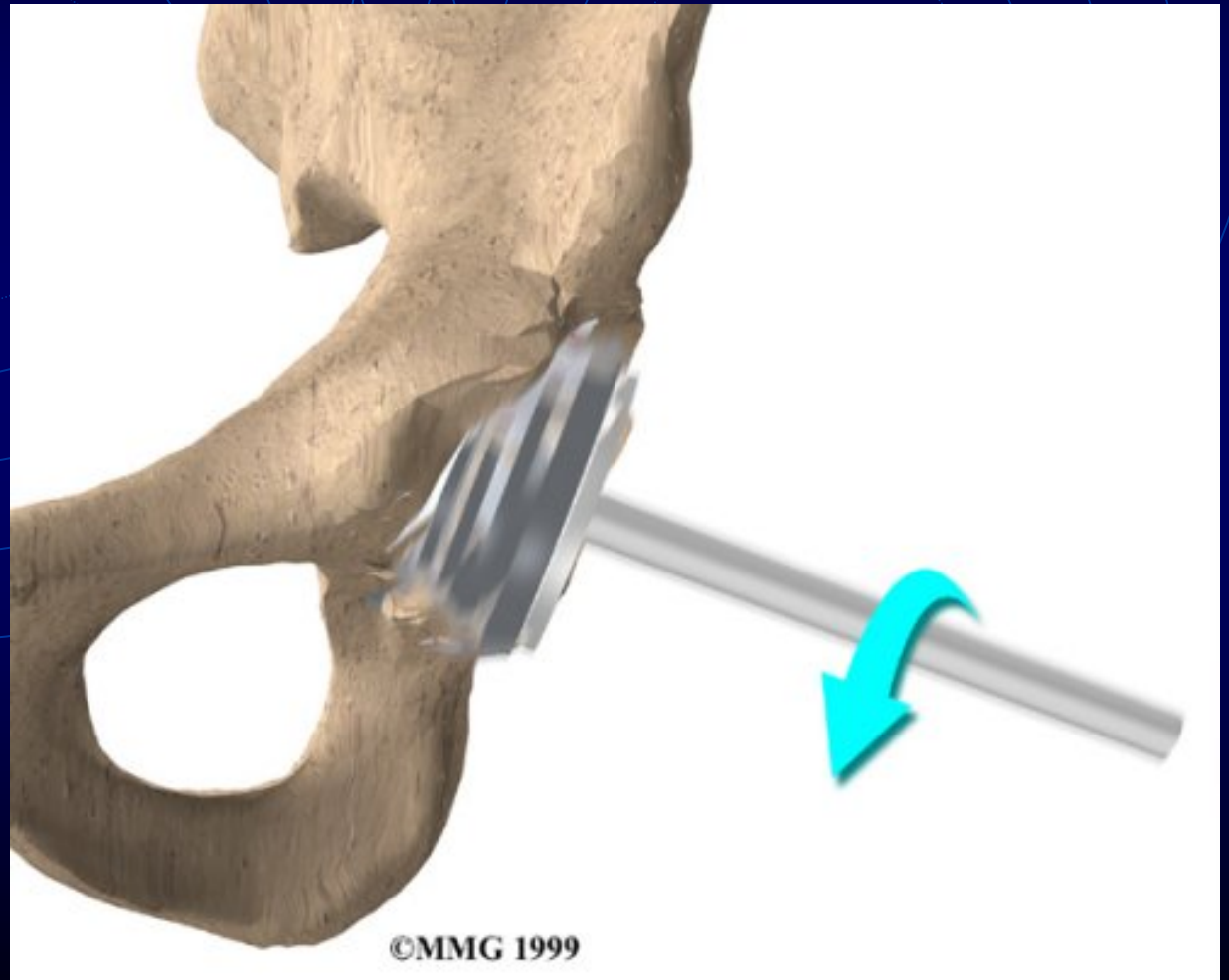
# *Acetabulum Reaming*

- Acetabular cup is reamed into a hemisphere
- Cartilage is removed



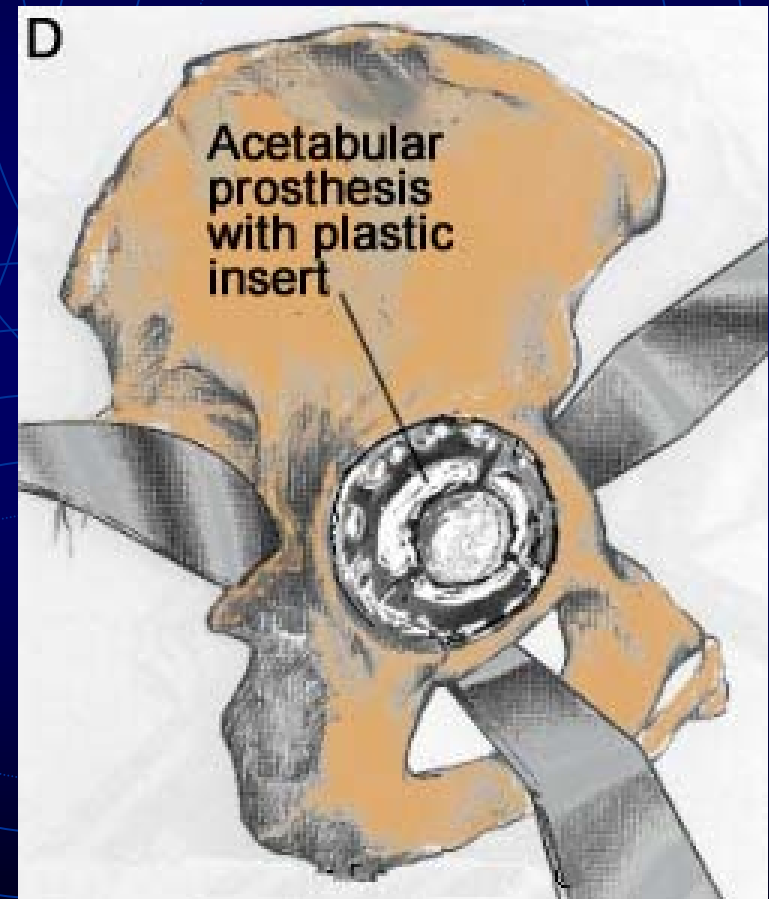
# *Reaming the Acetabulum*

- Lateral View

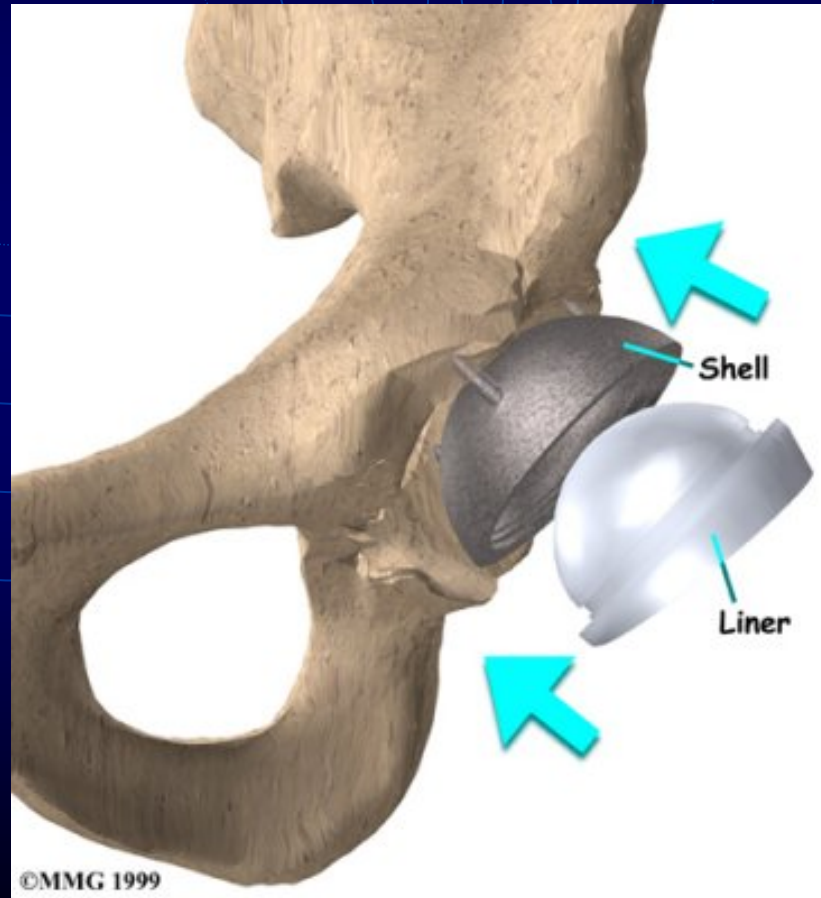


# *Inserting the Acetabular component*

- Acetabular shell
  - Porous coated
    - Press fit
    - Screws for stability
  - Cemented
- A hard smooth plastic liner is inserted into metal shell

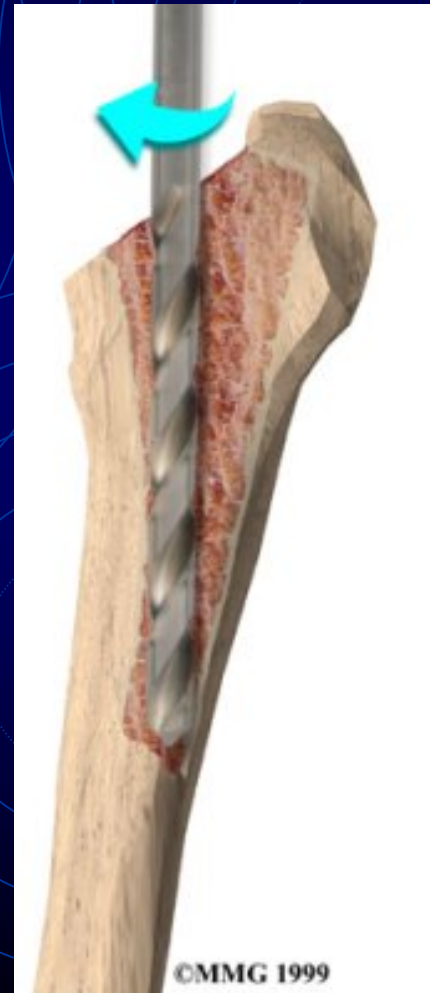

# *Insertion of Acetabular component*



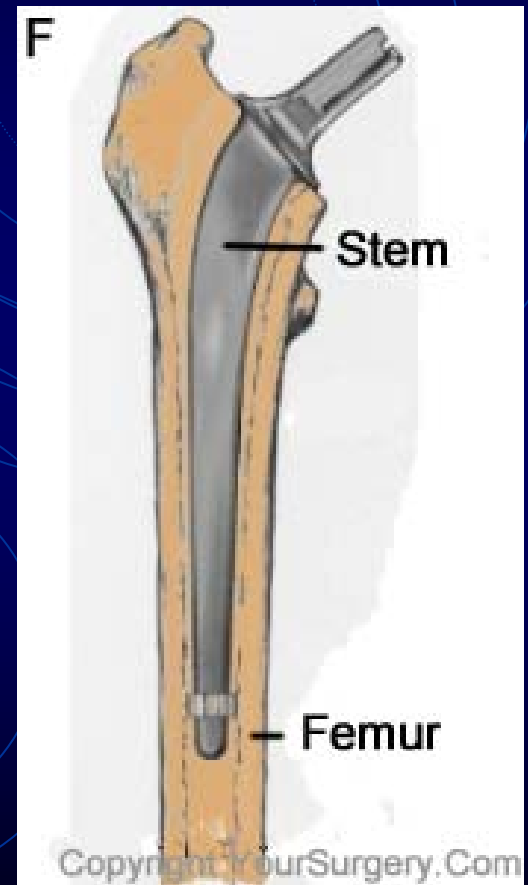
# *Reaming of Femoral Canal*

- Intramedullary canal finder
  - Manual insertion of a rod
- Distal intramedullary reaming with a straight reamer
- Rasping

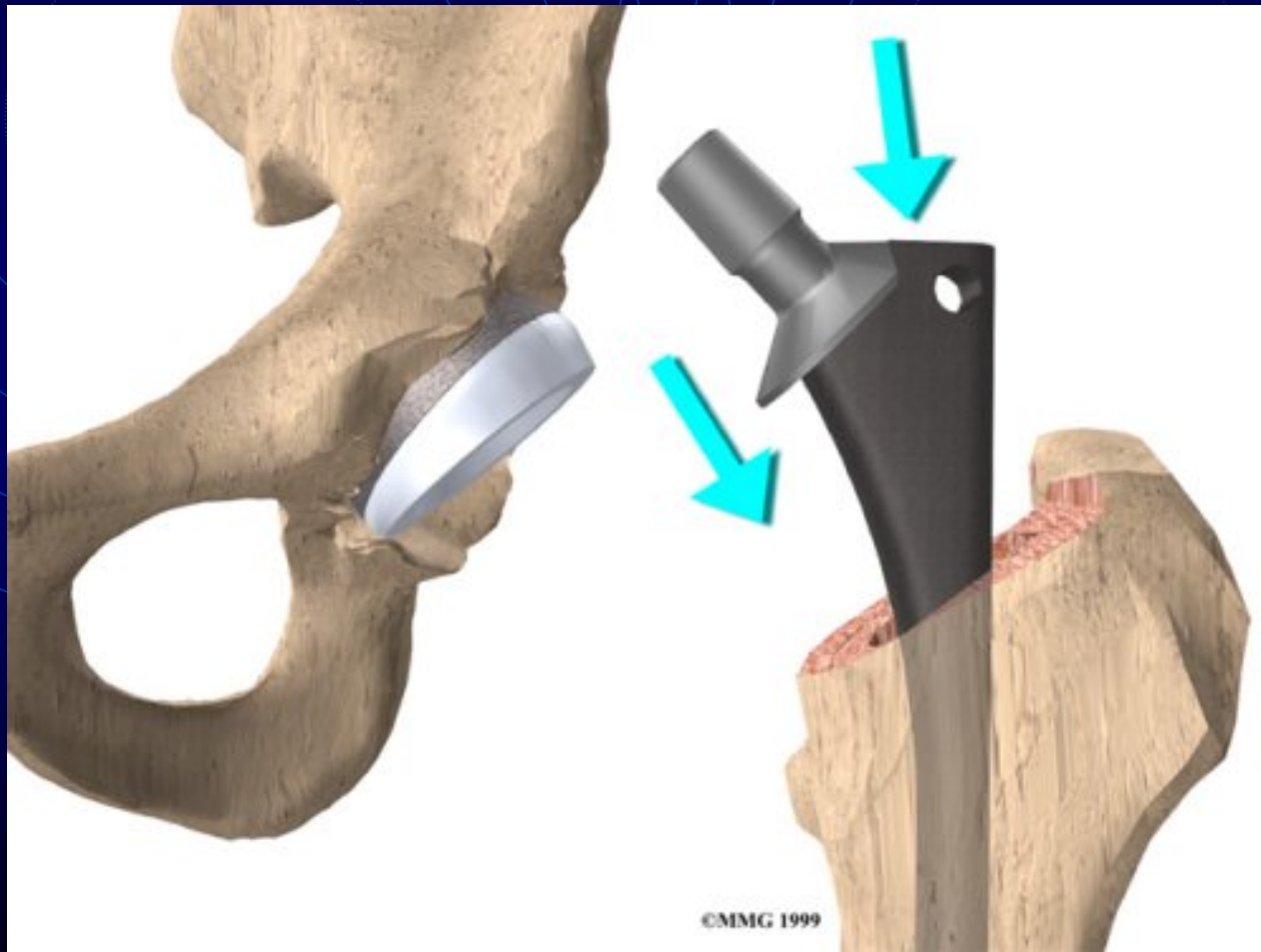


# *Femoral Stem Insertion*

- Press fit
- Cemented
  - Pressurization
    - Canal plug
    - Cement vacuum mix
    - Cement Gun

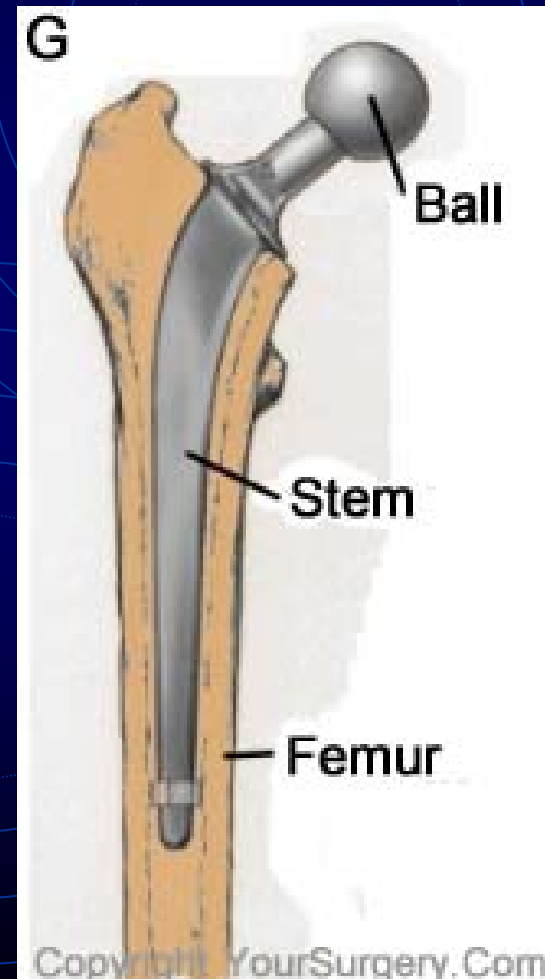


# *Inserting Femoral Stem*

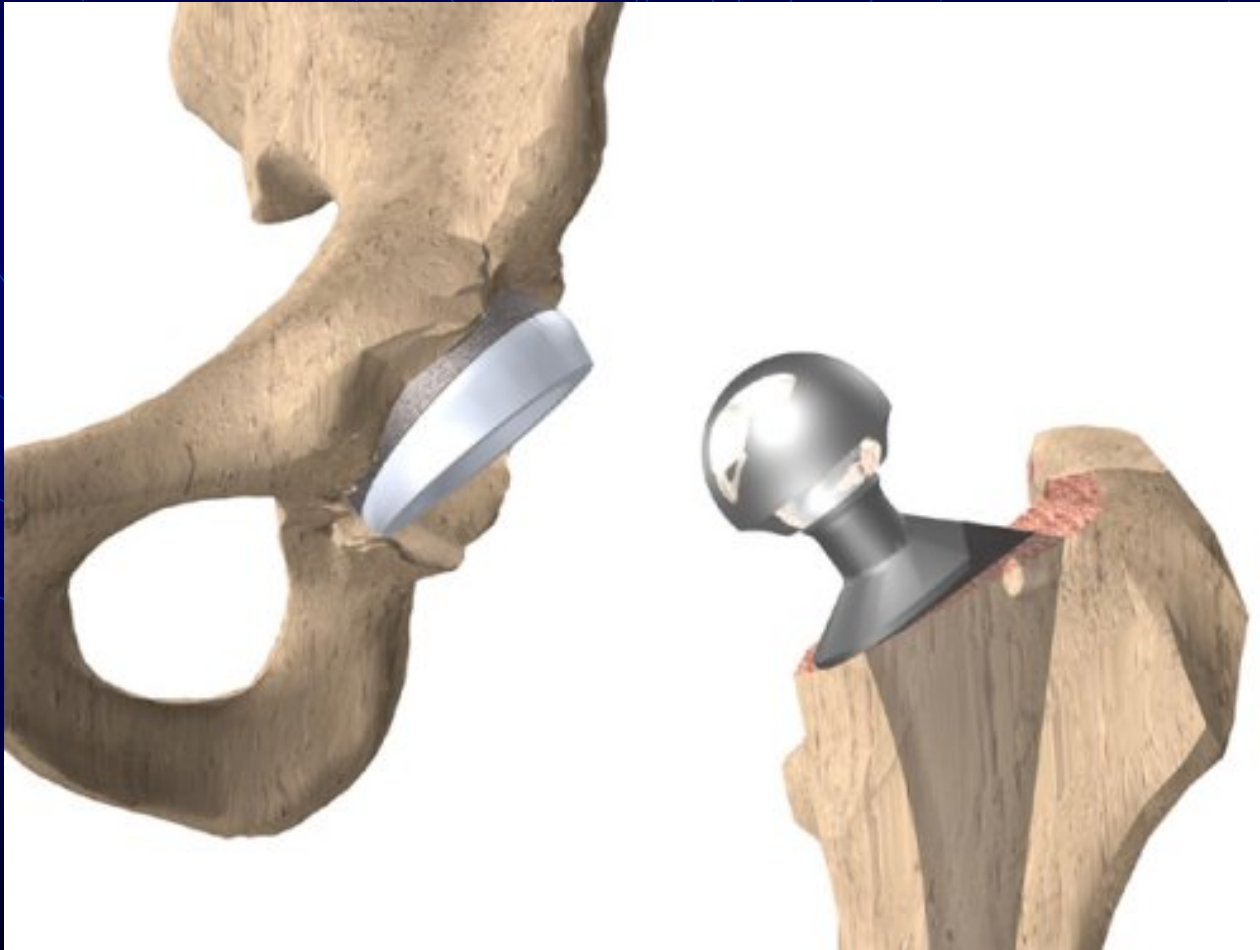


# *Femoral Head*

- A metallic head is attached to stem

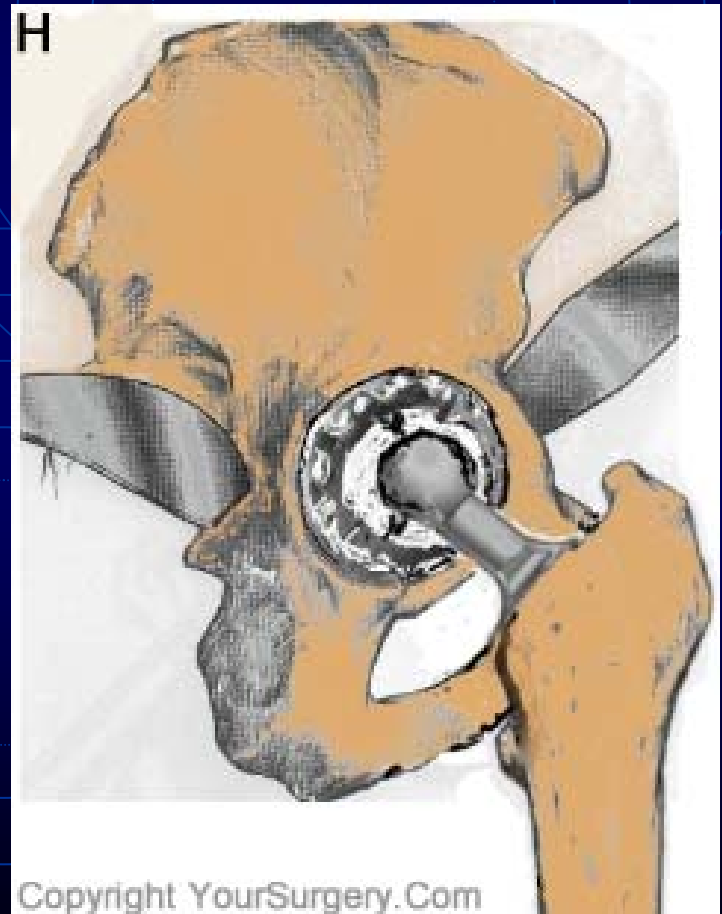


# *Attaching Femoral Head*

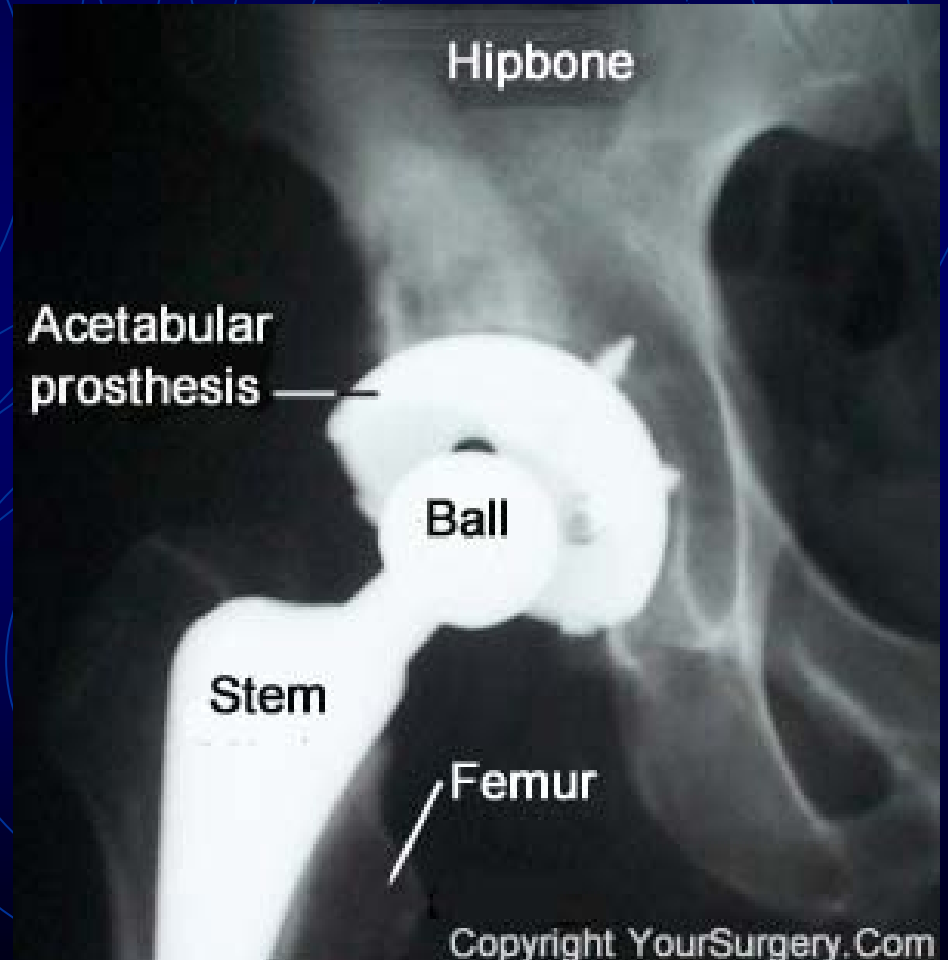
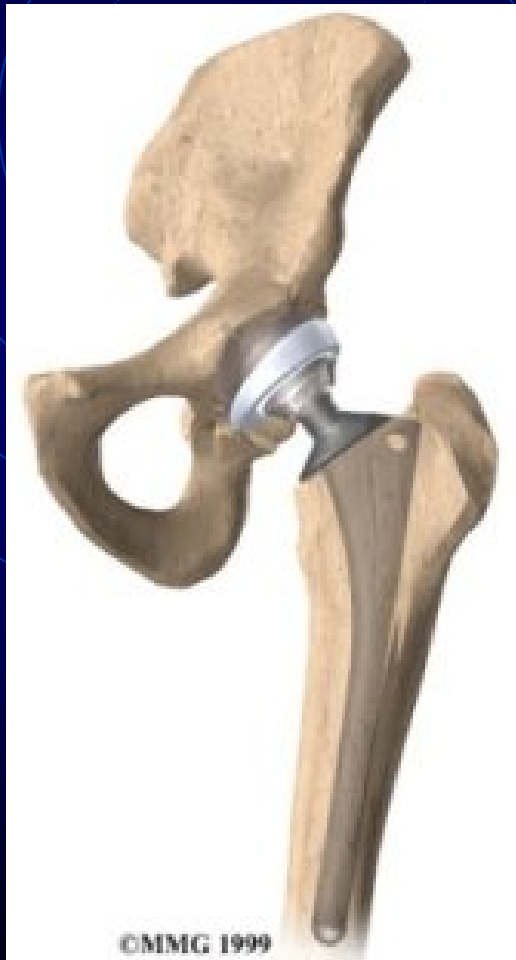
# *Hip Reduction*

- Ball is reduced into acetabular liner
  - Soft tissue tension is tested
  - Leg length may be a problem



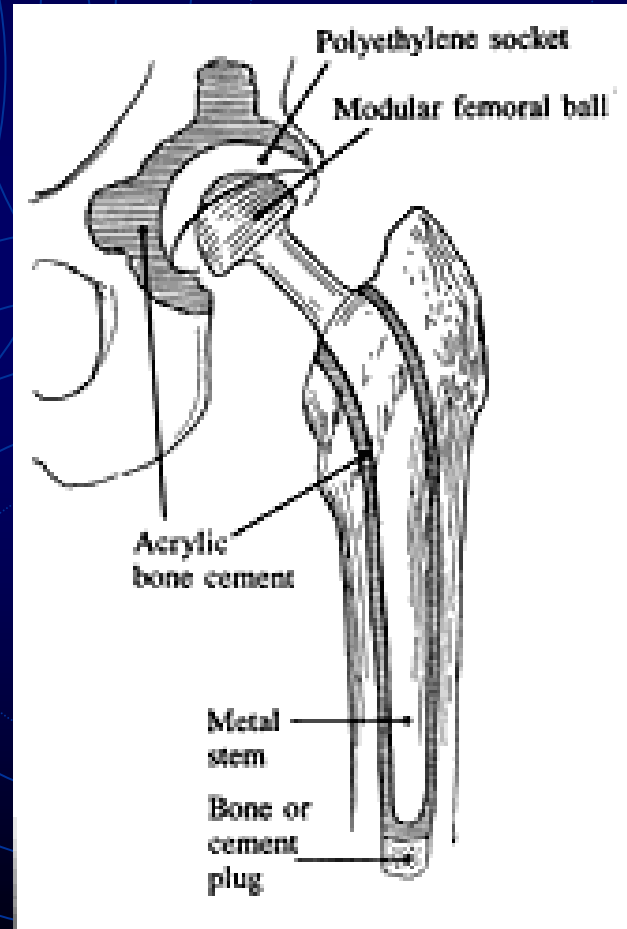
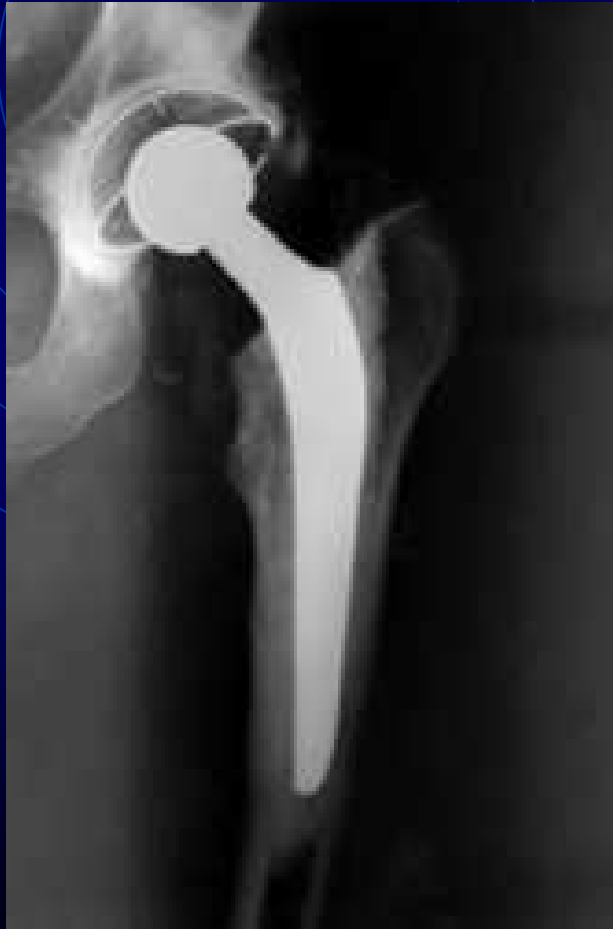# *THA*



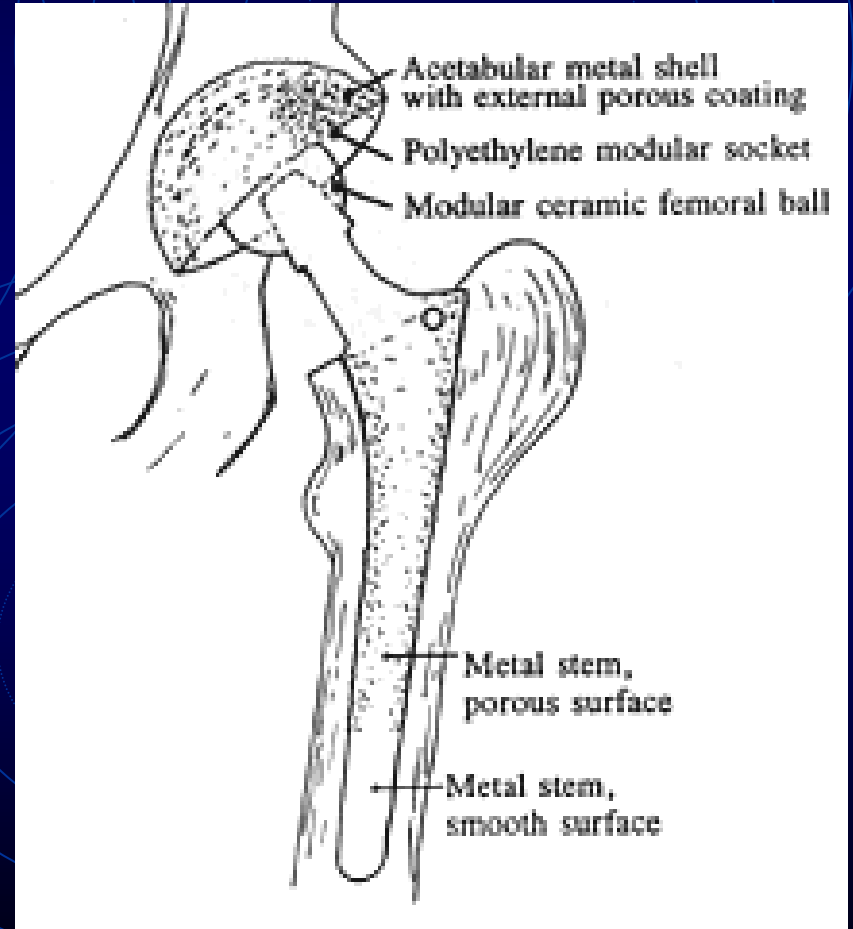
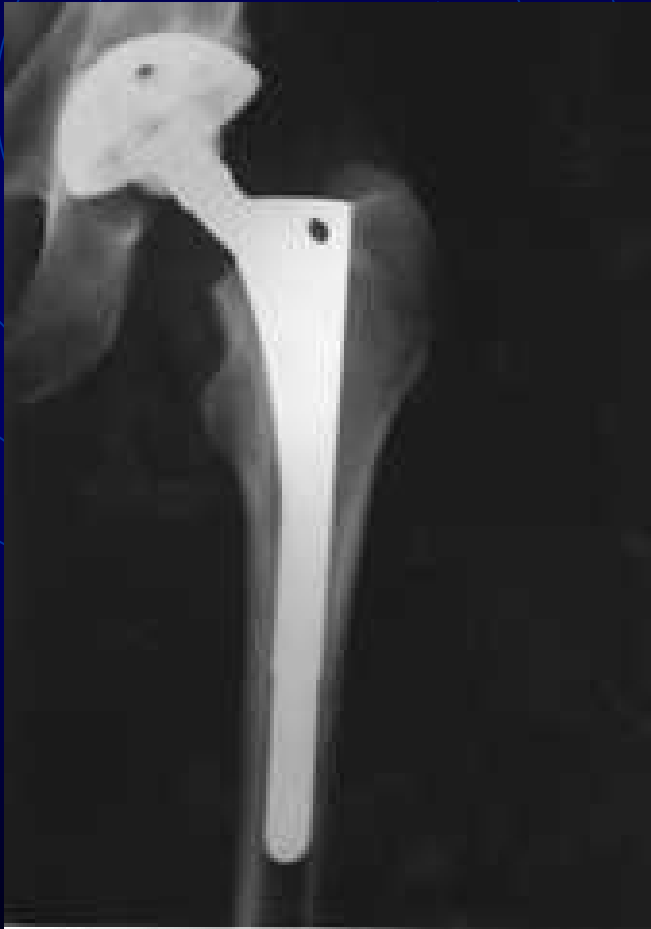# *Animation of hip replacement*

- <http://www.hipandkneesurgery.net/hip.html>

# *Acrylic Cement Fixation*

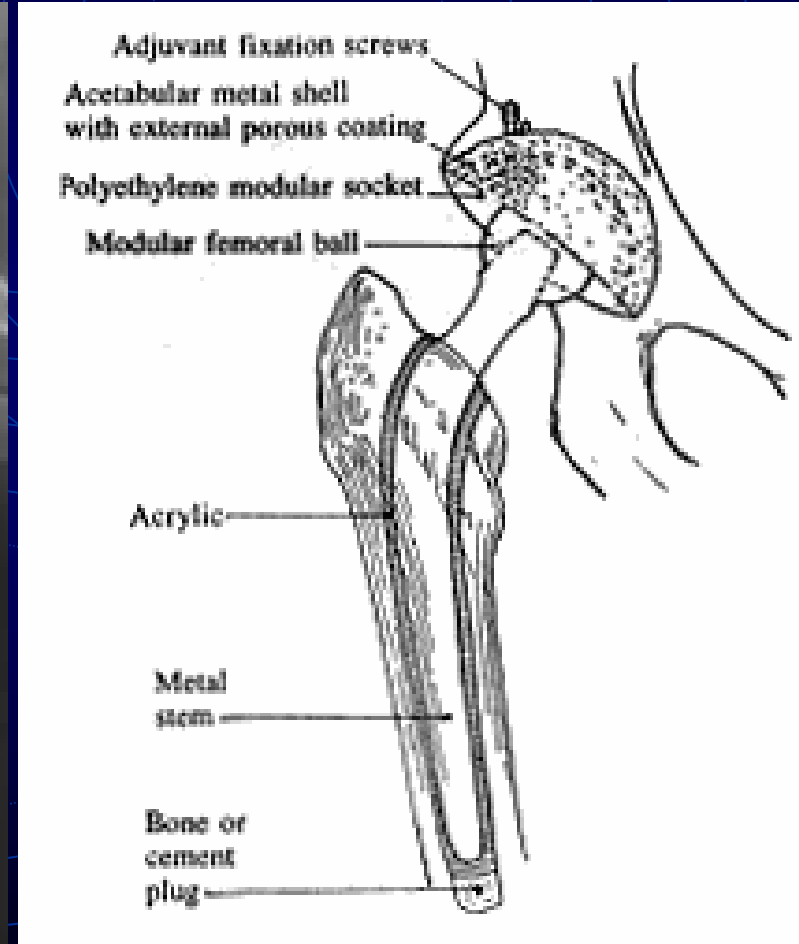
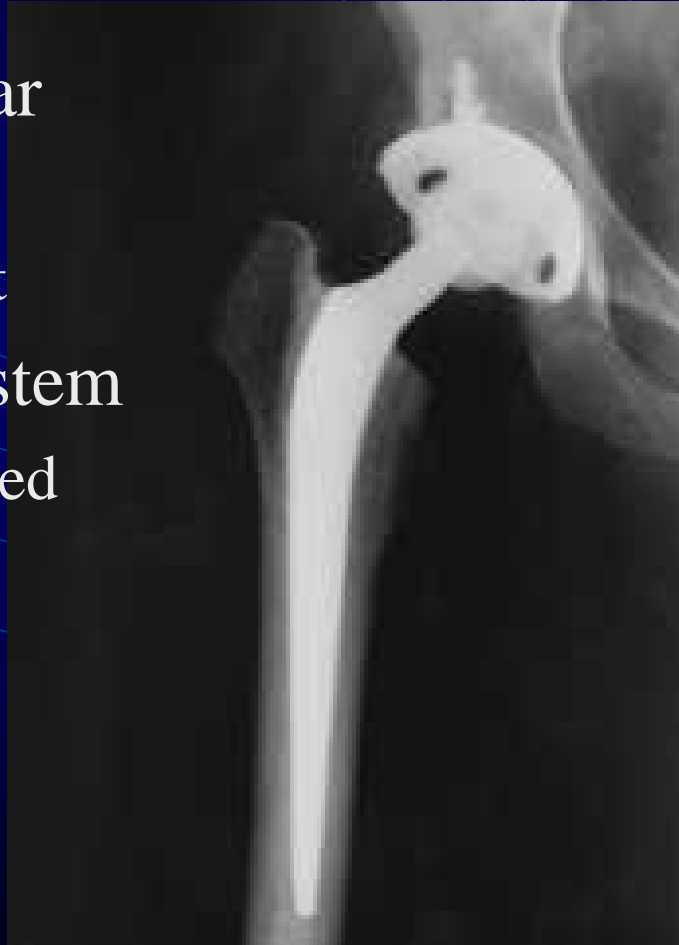

# *Cementless Fixation*



# *Hybrid Fixation*

- Acetabular cup
  - Press fit
- Femoral stem
  - Cemented



# *Care after Surgery*

- A suction drain
  - May be used for 1-2 days after surgery
- Intravenous fluids & antibiotics
- Pain medication
- Elastic stockings, compression stockings and blood thinners
  - To decrease chances of blood clots
- For first 6-8 weeks
  - Low sitting may cause dislocation

# *Care after Surgery*

- Physical therapy
  - Getting in and out of bed
  - Standing and walking
    - Crutches or a walker
- Discharge from hospital
  - Usually in 3-5 days
    - Continued PT, OT

# *Complications*

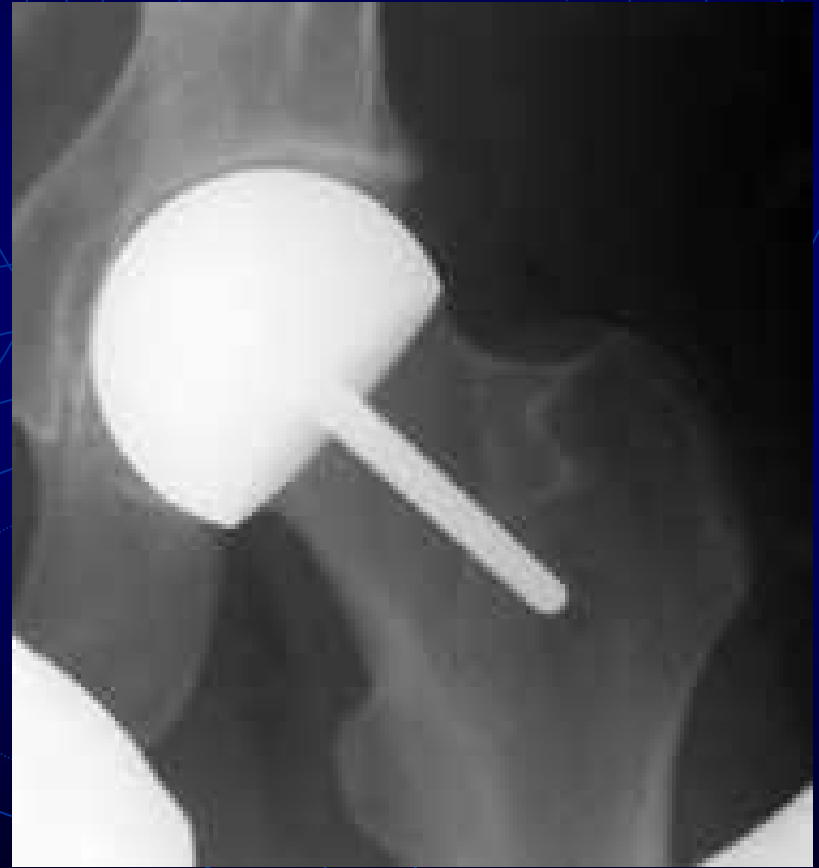- **Thrombophlebitis**
  - Blood clots within deep veins
  - Swelling of leg
    - Become warm to touch
    - Painful
  - May lead to pulmonary embolus and death
- Infection
- Dislocation
- Loosening

# *Other Types of Hip Replacement*

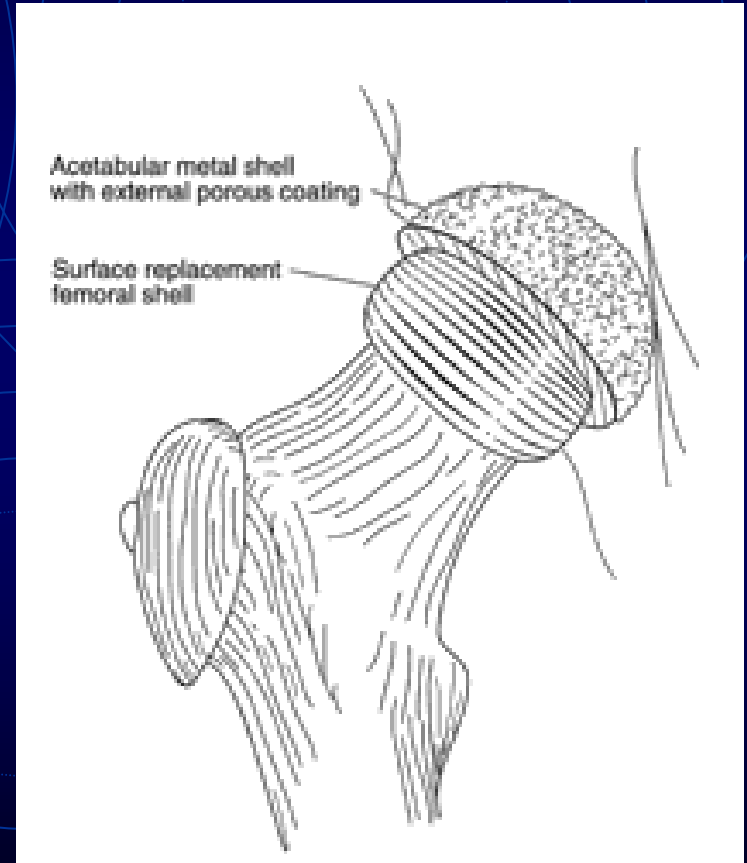
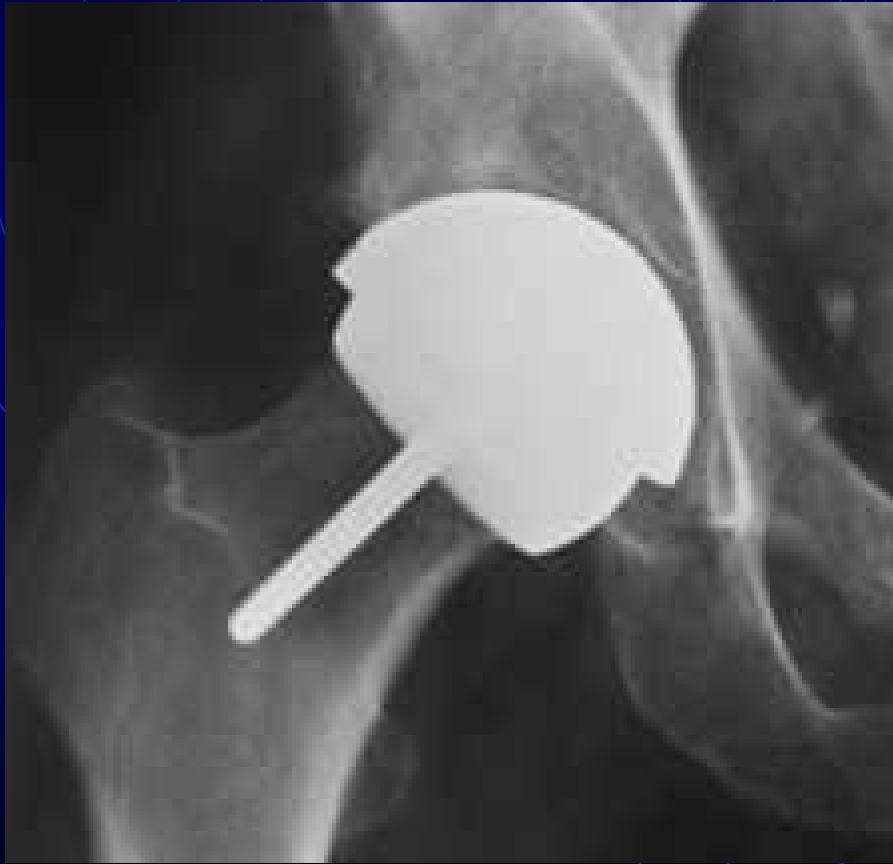- Surface Replacement of the Hip
  - In younger patients
  - Complication of a neck fracture
- Hemi-arthroplasty
  - Only the femoral side is replaced
  - When acetabulum is intact
  - May not be efficient in pain relief

# *Hemi-Surface Replacement*

- Bone stock preservation
  - Replacing only diseased part



# *Surface Replacement*



# *References*

- <http://www.hipandkneesurgery.net/hip.html>
- <http://www.yoursurgery.com/ProcedureDetails.cfm?BK=5&Proc=27>
- [http://www.jri-oh.com/hipsurgery/Hip\\_Types.asp](http://www.jri-oh.com/hipsurgery/Hip_Types.asp)

The background features a dark blue field with three sets of concentric circles in a lighter blue hue. Each set consists of four circles of varying radii. Dashed lines in the same light blue color extend from the centers of these circles towards the corners of the frame. The text 'The End' is centered in a white, italicized serif font.

*The End*